

See discussions, stats, and author profiles for this publication at: <https://www.researchgate.net/publication/350134390>

# Dog Circumanal Gland Tumor Surgery (Case Report) Journal of Veterinary and Animal Research

Conference Paper · March 2021

CITATIONS

0

READS

581

3 authors:



**Ibrahim Alrashid**

University of Basrah

131 PUBLICATIONS 42 CITATIONS

SEE PROFILE



**Alaa Ibrahim**

University of Basrah

12 PUBLICATIONS 3 CITATIONS

SEE PROFILE



**Rafid Majeed Naeem Alkhalifa**

University of Basrah

19 PUBLICATIONS 8 CITATIONS

SEE PROFILE

## Dog Circumanal Gland Tumor Surgery (Case Report)

Ibrahim MH Alrashid\*, Alaa A Ibrahim Aldirawi and Rafid M Naeem

*Department of Medicine and Surgery, College of Veterinary Medicine, University of Basra, Iraq*

**\*Corresponding author:** Ibrahim MH Alrashid, Department of Medicine and Surgery, College of Veterinary Medicine, University of Basra, Iraq, Tel: +9647703169873, E-mail: dr\_ibrahimveterinary@yahoo.ca

**Citation:** Ibrahim MH Alrashid, Alaa A Ibrahim Aldirawi, Rafid M Naeem (2021) Dog Circumanal Gland Tumor Surgery (Case Report). J Vet Ani Res 4: 102

### Abstract

Circumanal gland tumor is widely common in old age of male dog, present case of eight years age male dog, German shepherd breed. Have hard mass growth near anal orifice, it is long polyp, painless, and normal skin coloration. After incision of tumor, and histopathology, it was reveal benign adenoma according to tumorous behavior in histopathology section. Blood parameters were a normal value, after recovery period the dog returned to normal health and activity. In conclusion the Circumanal gland adenoma was revealed non dangerous to old male dogs.

**Keywords:** Circumanal Gland; Tumor; Adenoma

### Introduction

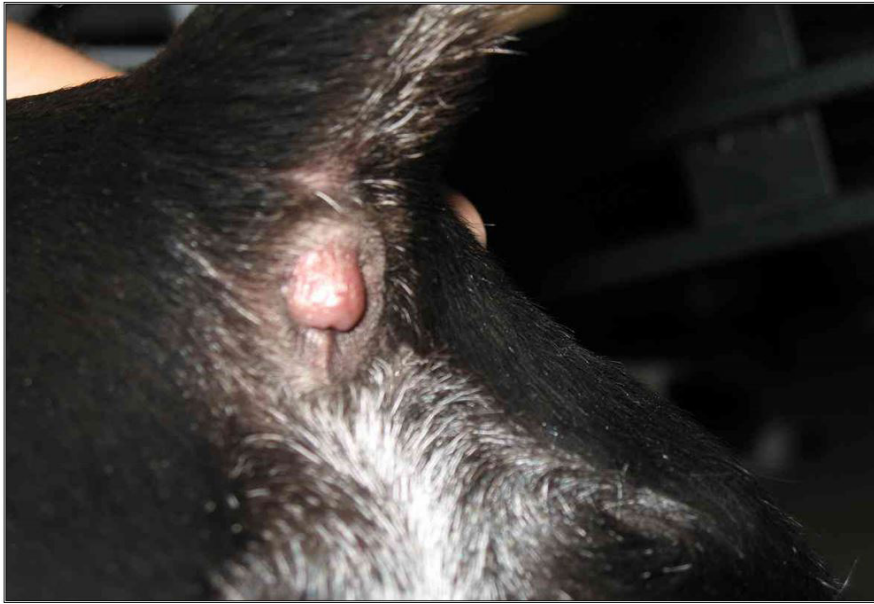Circumanal gland are modified sebaceous gland and typically located in the premium region [1]. The gland also located in the other area such as dorsal and ventral tail base, upper thigh, dorsal medline and lumber region [2]. The gland produce a foul smelling substances after anal sac empties [3]. Circumanal gland cells is similar to hepatocytes in appearance, therefore called hepatoid gland tumor in case adenoma or malignant [4]. Most Circumanal gland tumors are benign (adenoma), rarely were malignant (adenosarcoma) [5]. The development of Circumanal gland adenomas occurs in old ages of dogs, specially in male dogs [6]. Circumanal gland adenoma is a polyp arises from perineal region near anal orifice, painless, and hard mass [7].

Most veterinary surgeon remove this tumor by complete incision from epidermis and use electrocutery application to prevent tumor recurrence tumor growth [8]. Other veterinary surgeon or veterinary oncologist are use hormonal therapy, neutering, and chemotherapy [9].

### Materials and Methods

Eight years age male dog was German shepherd breed, healthy status which suffered from abnormal mass growth near anal orifice. Surgical instruments were used, anesthesia agents (ketamine and xylazine) to anesthetized the patient Figure 1.

The dog was under anesthesia (15 mg ketamine+ 3 mg xylazine) /Kg BW [10]. Cleaned the area to prepared of surgery, the polyp was removed by surgical incision [11], and caustic soda (Na OH) 10% was cauterized after incision to killed tumorous cells [12]. Post surgery care were used course of antibiotic and anti inflammatory drugs. The mass of tumor was kept in 10% neutral formalin and prepared to histopathology and stained with hematoxilin and eosin stain [13]. Blood parameters were examined [14].



**Figure 1:** The site of tumor, note the tumor mass under tail

## Results

Blood parameters were estimated in the following tab.

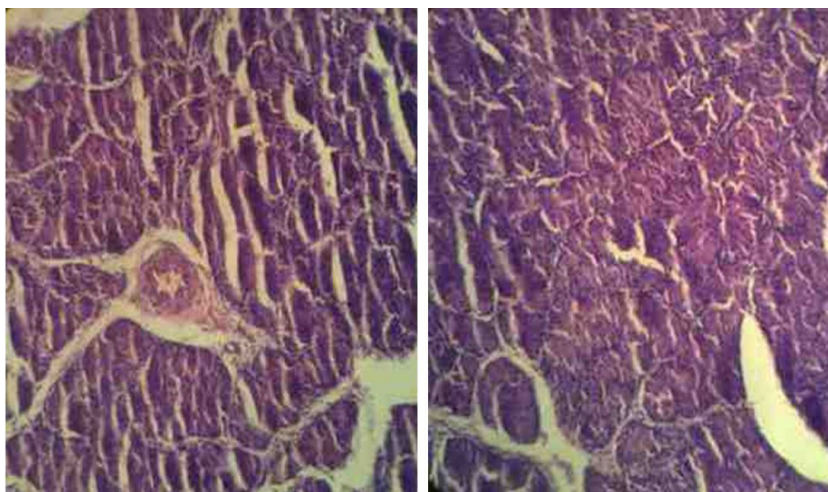
Blood parameters before surgery

Parameters	RBCs*10 <sup>12</sup>	WBCs*10 <sup>9</sup>	Hb g/dl	PCV
	8.49	11.4	17.8	71

Blood parameters post surgery after 4 months

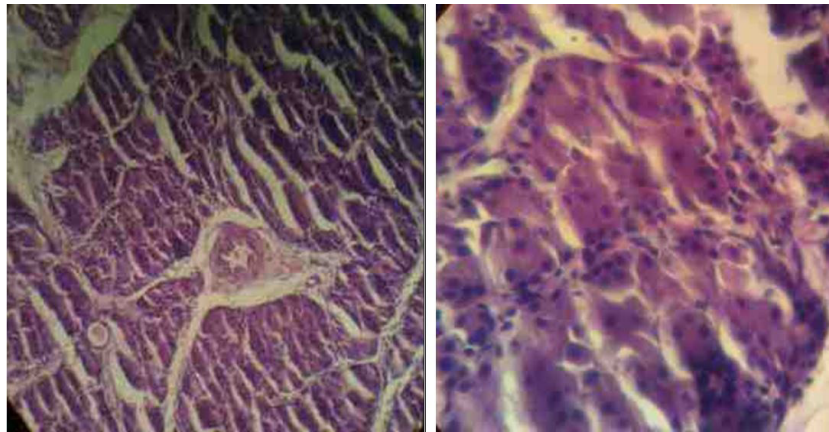
Parameters	RB Cs*10 <sup>12</sup>	WBCs*10 <sup>9</sup>	Hb g/dl	PCV
	8.32	11.3	18.1	67

Histopathology picture of the tumor Figure 2.



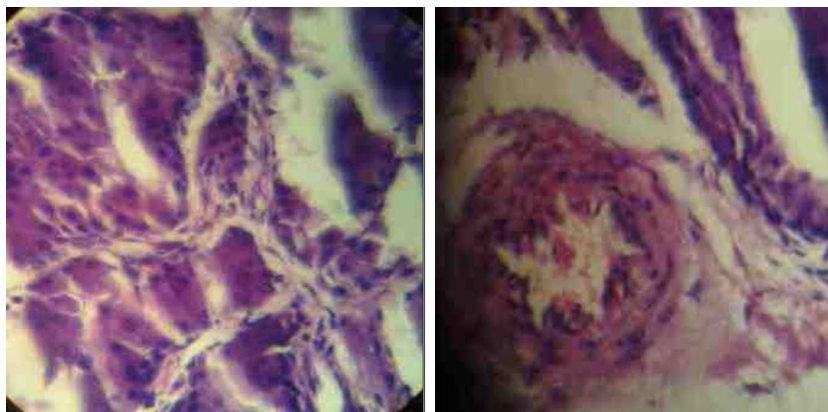
**Figure 2a:** Tumor of polyp, note: fields of glandular structure, separated fibrous tissue around artery, stain with H &E X40

**Figure 2b:** Glandular structure in between fibrous tissue, prominent endothelial cell proliferation, stain with H &E X 10



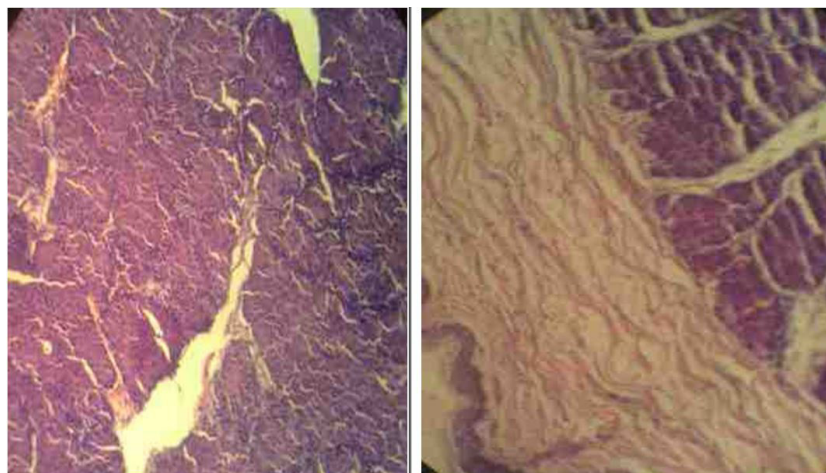
**Figure 2c:** Tumor of polyp, note: fields of glandular structure, separated fibrous tissue around artery, stain with H &E X10 (same Figure 2a)

**Figure 2d:** Field of tumor show glandular structure of tumor, prominent fibrous tissue stroma among glands, no evidence of malignancy, stain with H &E X100



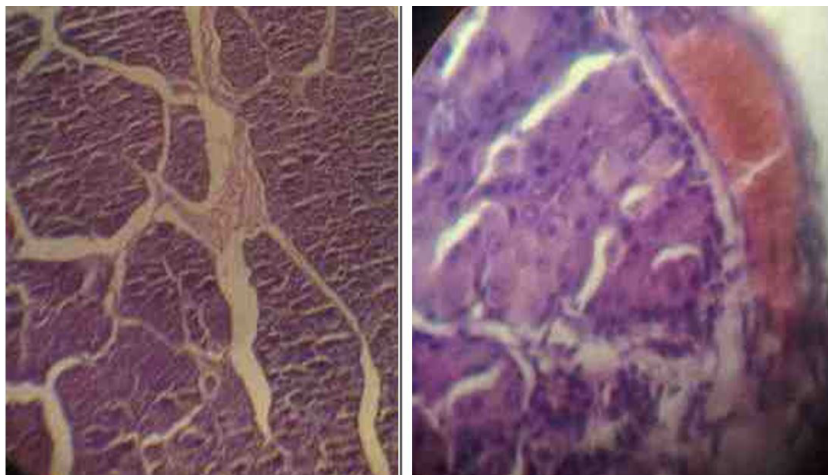
**Figure 2e:** Field of tumor show glandular structure of tumor, prominent fibrous tissue stroma among glands, no evidence of malignancy, stain with H &E X400 (same Figure 2a)

**Figure 2f:** A large artery in the tumor with prominent media and endothelial cells stain with H &E X400



**Figure 2g:** Section show of glandular structure of tumor with separated fibrous tissue in some mono-nuclear cell, stain with H &E X40

**Figure 2h:** In area show squamous cell keratinization farther than anal gland tumor, stain with H &E X40



**Figure 2i:** Section, show of glandular structure of tumor with sperated fibrous tissue in some mono-nuclear cell, stain with H &E X100

**Figure 2j:** An area of tumor with congested large blood vessel, stain with H &E X100

## Discussion

The method of surgical operation was similar to other surgeon method such as Cotchin and Buzzard [3], there are no different with other surgeon, an incision was used only. In present study wasn't used hormonal therapy as a medicine treatment; while other studies were used hormonal therapy as Atoji, *et al.* [5] was used estrogen (Esteron<sup>R</sup>) to decrease testosterone hormone because of the Circumanal gland tumor related with increase activity of testes in male dogs [8]. Researchers were used chemotherapy to inhibit cancerous cells growth in other study whereas no used chemotherapy in present study. Chemical caustic agent (Na OH) caustic soda 10% was used in this study locally post incised the tumor to killing other cancerous cells in root of the tumor mass and prevent re-growing tumor in area, other researchers were used electric caustic application (electrocutey), but this technique may destroyed more neighbor healthy tissue.

Histopathology images were showed typically benign circum anal gland tumor, this result no different with other researchers, recurrent growth mass tumor wasn't in this case during follow up four months, some reports were reveal to 9% may recurrent, and other record a circum anal gland adenoma convert to adenocarcinoma with ratio 3%.

## Reference

1. kiran MM, Karaman F, Hatipoglu F, Koc Y (2005) malignant fibrous histocytoma in a dog: case report. *Vet Med Czech* 50: 553-7.
2. Goldschmidt M, Shofer F (1992) skin tumor in dog and cat. *JA Vet Med* 10: 205-9.
3. Cotchin E (1947) some glandular tumor of dog. *Vet Res* 57:115-17.
4. Dedham Veterinary Association47-A55.com
5. Atoji Y, Yamamoto Y, Suzuki Y(1998) Apocrine Sweat Gland in the Circumanal Gland Tumor of Dog. *Ant. Res.* 255: 403-8.
6. toapayohvets.com
7. Vandis M (2010) Canine Circumanal Gland adenoma ( cytologic clues) . *J Am Vet Med Asso* 233: 825-31.
8. Pessina A, Richard F, Hoyt A, Irwin J, Traish A (2006) Different Effect of Estrodiol, Progesterone, and Testosterone on vaginal structure Integrity. *Endo J* 147: 61-9.
9. Harari J (1996). *Small Animal Surgery*. 2nd ed. William and Wilkins Co. Sydney, Tokyo, Wroclaw: 33-47.
10. Argyle D., Malcon J. and Turek M (2008) *Decision making in Small animal Oncology*. Black-Well pub: 159-215.
11. Bancroft JD, Stevens A, Pears AG (1975) *Histochemical techniques*, 2nd. Butter-worth Co ltd Great Britain 33-5.

- 
12. Coles EH (1986) Veterinary clinical pathology, Fourth Edition WB Saunders.
  13. Lee L (2006) Veterinary Anesthesiology. born veterinary technical hospital, college of veterinary medicine, Oklahoma State University. 4th ed Mac Donald Co: 32-4.
  10. Argyle D., Malcon J. and Turek M (2008) Decision making in Small animal Oncology. Black-Well pub: 159-215.
  14. Meakins J, Masterson B (2005) Prevention of post operative infection. In basic surgical operative consideration: 13-33.